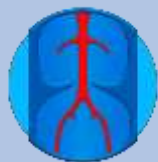

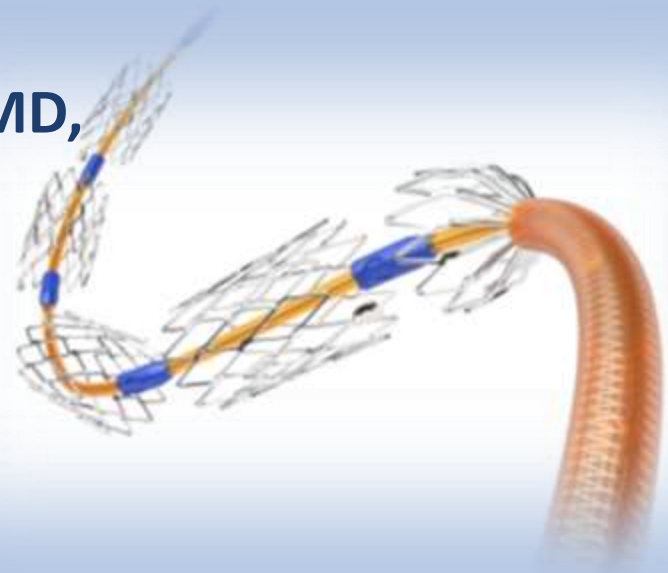
The logo for LING, featuring a stylized blue and red shape resembling a flame or a brushstroke, with the word "LING" in white capital letters overlaid.

LING

# Spot Stenting with VascuFlex Multi-Loc



**P. Goverde MD, K. Taeymans MD,  
K. Lauwers MD**  
*Vascular Clinic ZNA  
Antwerp, Belgium*



# Disclosure

**Speaker's name: Peter Goverde**

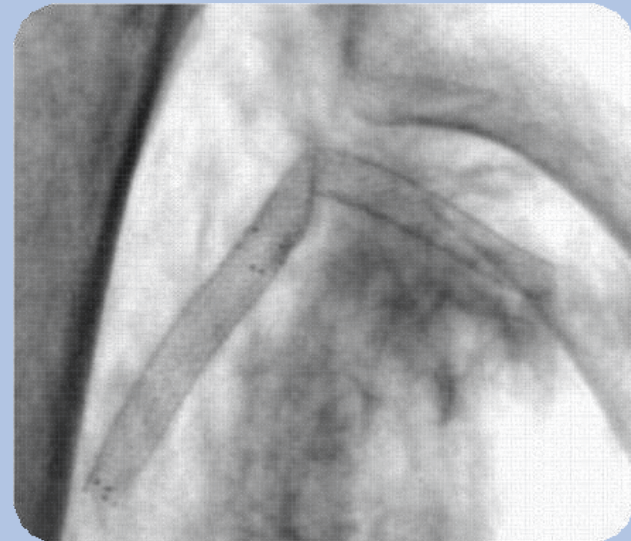
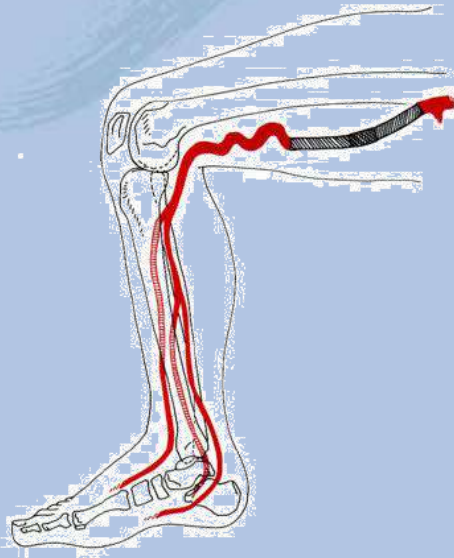- **I have the following** potential conflicts of interest to report:

**Grant/Research Support/Consulting Fees/Honoraria:**

**Abbott Vascular; Angioslide; Bard Peripheral Vascular; Bentley; B Braun endovascular; Cardionovum; Cordis Cardinal Health; CTI; IMDS; Ivascular; Getinge group; Stille; Ziehm Imaging**

# Anatomical background

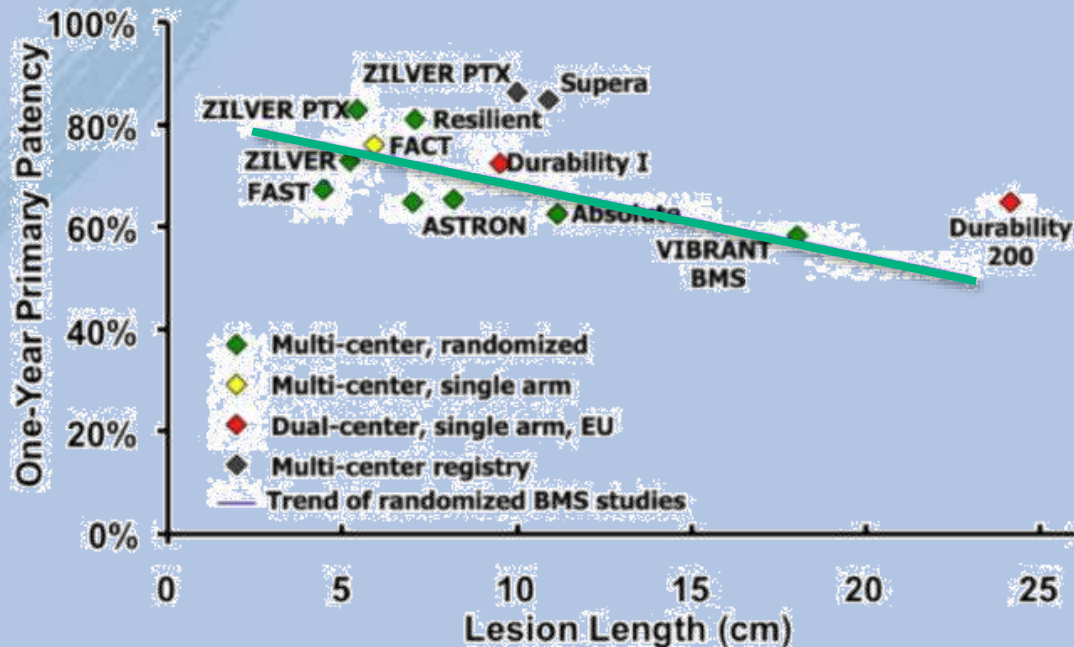Implants reduce vessel compliance and the ability to absorb deformation



1. Smouse HB Changes in major peripheral arteries during joint movement before and after stent placement in the cadaver model. TCT 2004

# Limitations of stenting strategies

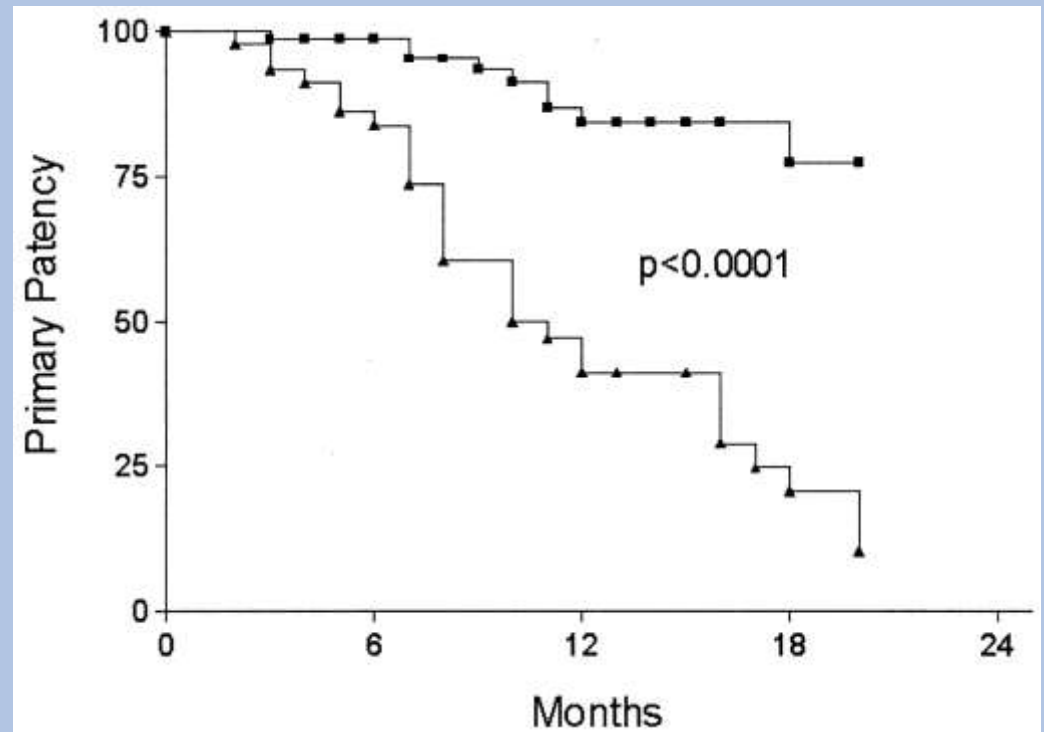
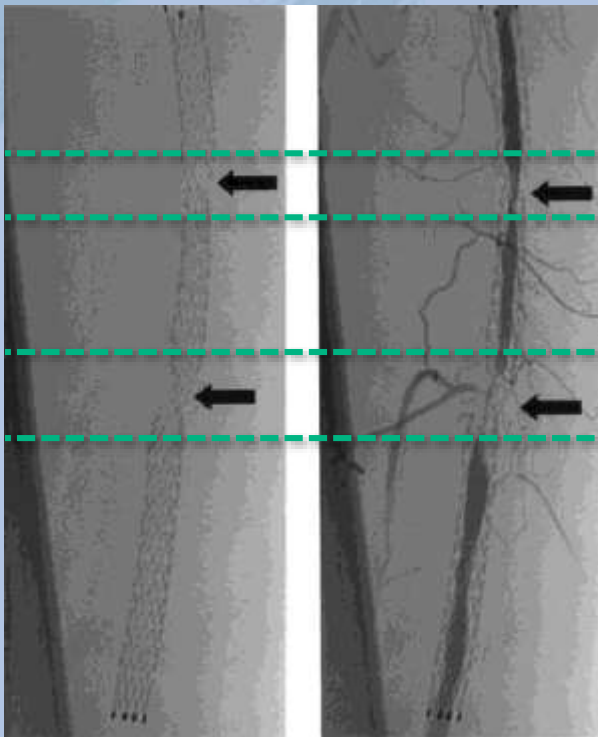
Patency rates decrease with stent length



Because of long lesions and/or because of long stents?

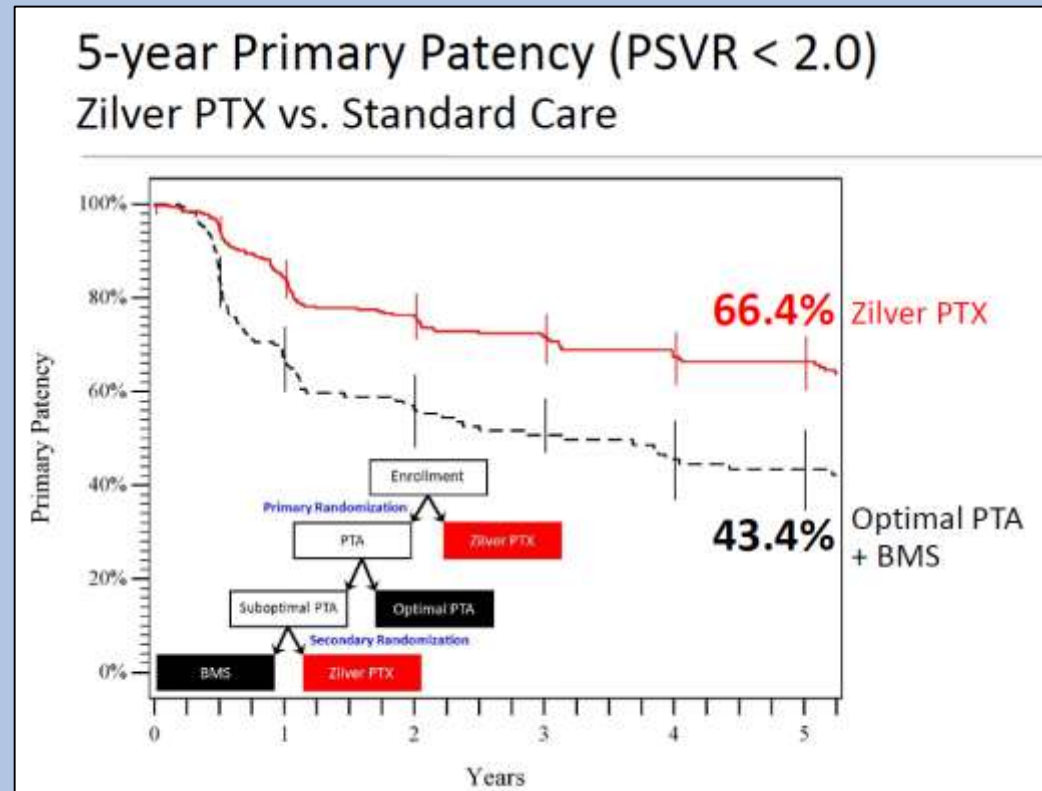
# Limitations of stenting strategies

Stents may fracture depending on design, stent length, site, movements of vessels and overlap



# Limitations of stenting strategies

Patency rates decrease over time even with DES, due to permanent trauma from chronic outward force of common oversized Nitinol stents.

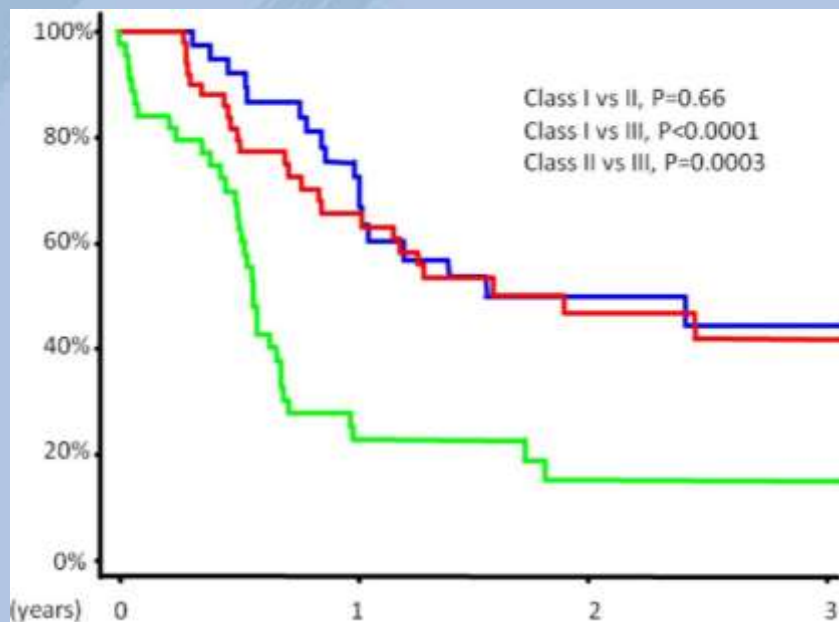


1. Dake M et al. Durable Clinical Effectiveness With Paclitaxel-Eluting Stents in the Femoropopliteal Artery: 5-Year Results of the Zilver PTX Randomized Trial; Circulation. 2016; CIRCULATIONAHA.115.016900.

# Limitations of stenting strategies

Treatment of **instent restenosis (ISR)** is limited (costly, time consuming, high recurrency rate).

Freedom from Recurrent ISR by ISR Class



## ISR 2-year recurrence

- 49.9 % in class I (focal)
- 53.3 % in class II (diffuse)
- 84.8 % in class III (occlusive)

1. Tosaka A et al. Classification and clinical impact of restenosis after femoropopliteal stenting. J Am Coll Cardiol. 2012 Jan 3;59(1):16-23
2. Laird JR et al. The treatment of femoropopliteal in-stent restenosis: back to the future. J Am Coll Cardiol. 2012 Jan 3;59(1):24-5



# Limitations of stenting strategies

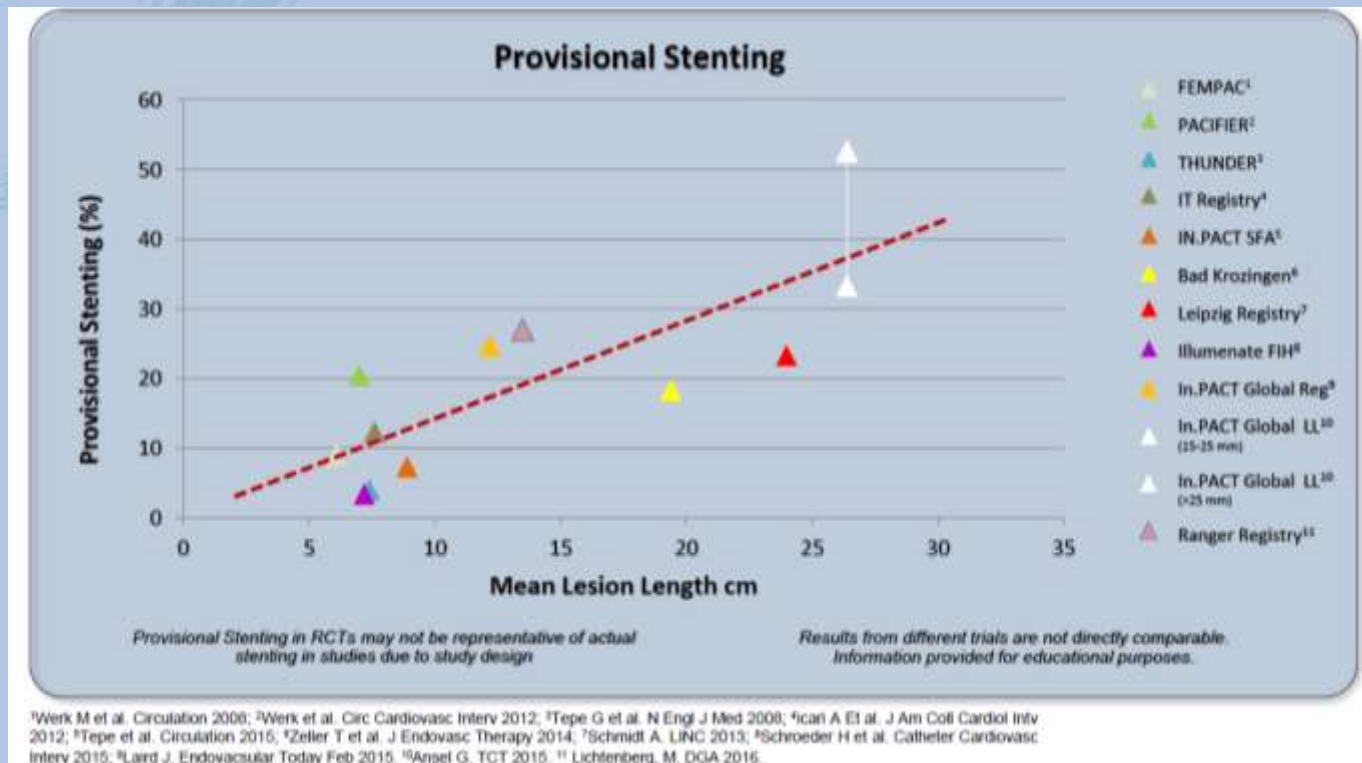
Stents may limit surgical option by blocking reconnection site for surgical bypass.





# Limitations of DCB only strategy

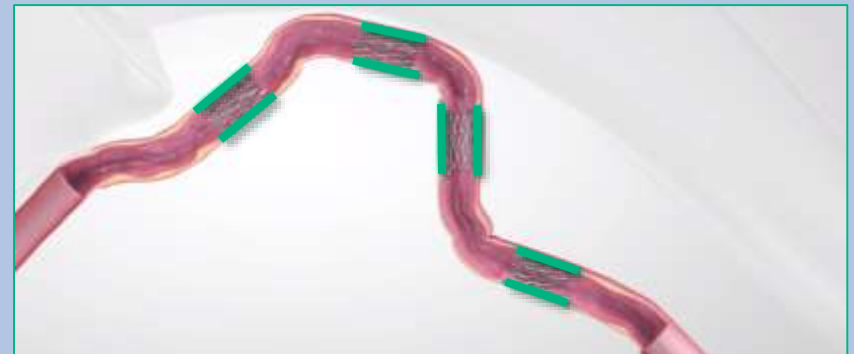

DCB therapy is limited as scaffolding is needed in up to 50% of cases with long lesions.



# Shorter is better?!

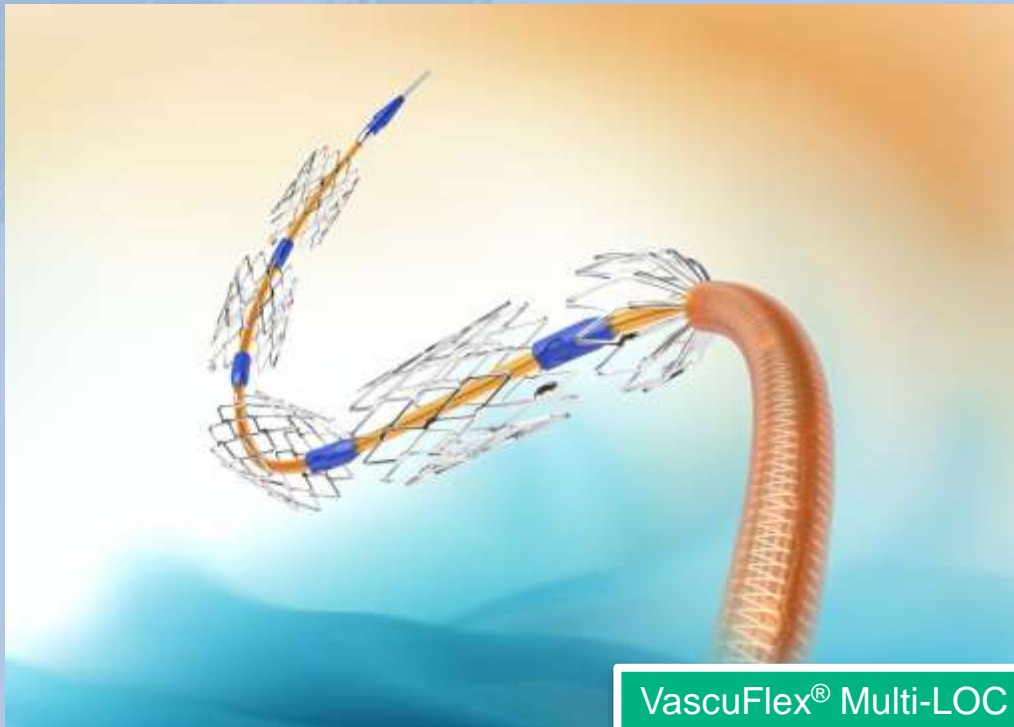
Short stents may have several advantages:

- Less acute and chronic trauma on vessel wall because of less material
- Less impact on biomechanical properties of vessel because of gaps between stents
- Individual stenting strategy depending on lesion morphology



# Spot Stenting Device

## B. Braun VascuFlex® Multi-LOC



VascuFlex® Multi-LOC

- Six stents on one delivery system
- Each stent is freely positionable
- Each stent has high radial force (closed cell design)
- It is made to cover long lesions with less material
- It maintains the natural vessel movement

# Spot Stenting Device

## B. Braun VascuFlex® Multi-LOC

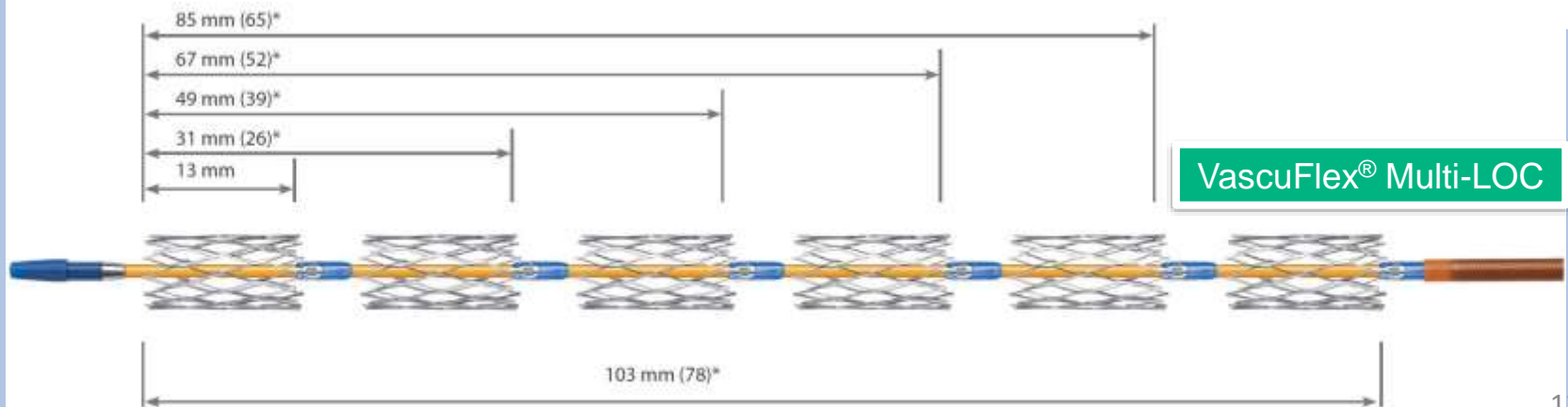

Stent-Diameter: 5 – 8 mm

Stent-Length: 6x 13 mm

Guide Wire Compatibility: 0.035"

Sheath Compatibility: 6F

Shaft-Length: 80 cm / 130 cm



\* total length of the stents with no distance in between

# LOCOMOTIVE study

- Objective:** VascuFlex® Multi-LOC in de-novo and restenotic lesions in SFA and P1, P2, P3
- Number of Patients:** up to 500 patients worldwide
- Inclusion Criteria:**
- Lesions with unsatisfying angiographic results due to dissection or recoil after POBA/DCB
  - Reference Vessel Diameter: 4.0 mm – 7.0 mm
  - Lesion length: 2 cm – 27 cm
  - Rutherford classes 2 – 5
  - At least 2 stents (distance min. 0,5 mm)
  - Diameter stenosis pre-procedure must be  $\geq 70\%$

# LOCOMOTIVE study

Primary Endpoint: TLR at 6 months

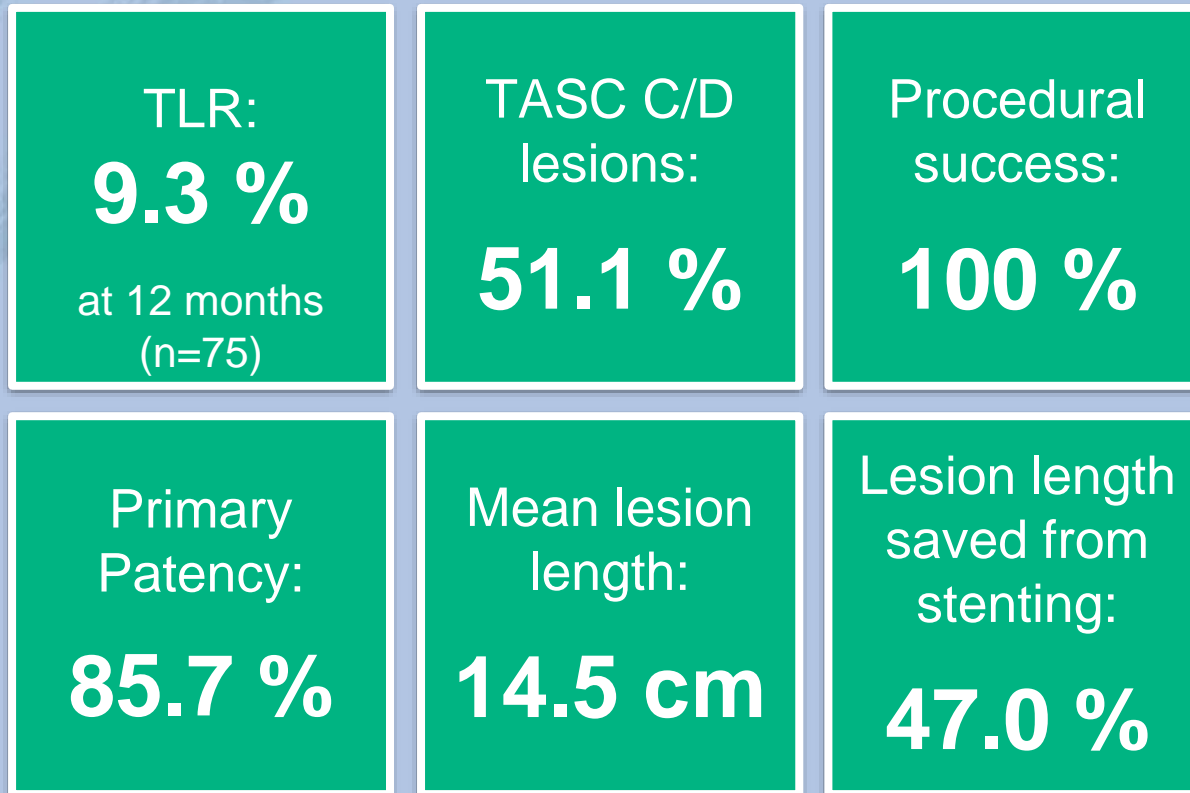
Sec. Endpoints:

- TLR at 12 months
- Walking distance (pre & post, 6 & 12 months)
- ABI (post, 6 & 12 months)
- Patency (Duplex ultrasound at 6 and 12 months)
- Rutherford classifications at 6 and 12 months
- Rutherford classification distribution change at 6 and 12 months
- Amputation rate at 6 and 12 months
- Quality of Life assessment (questionnaire post & 6 months)



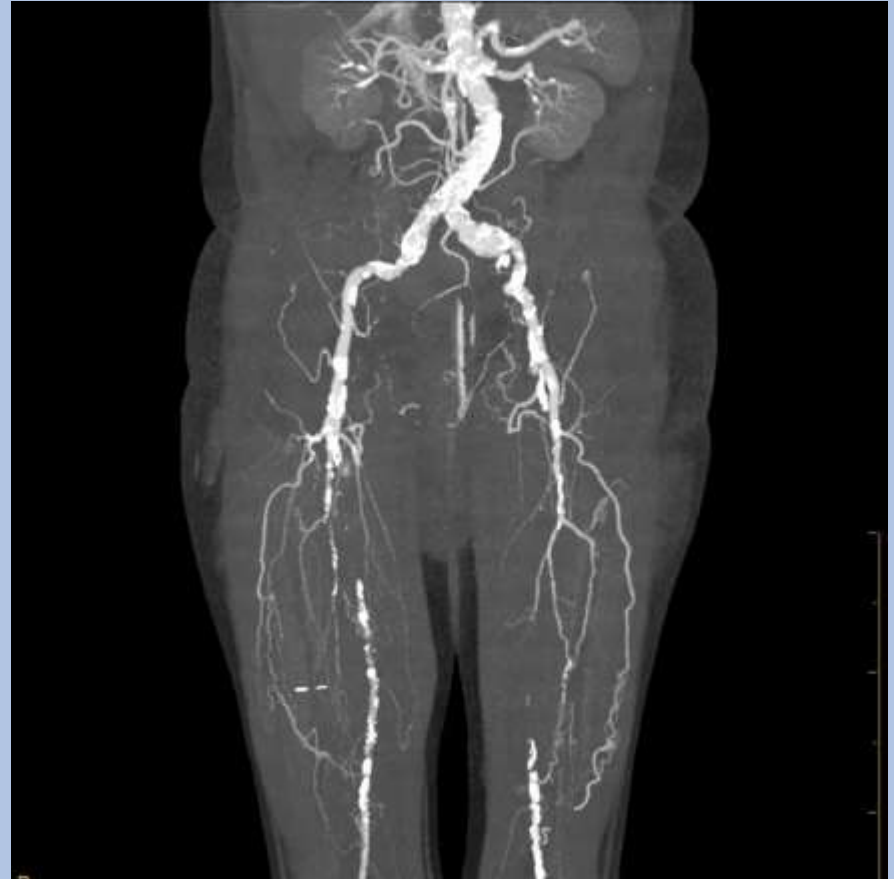# LOCOMOTIVE study

## 12 month results (N=75)


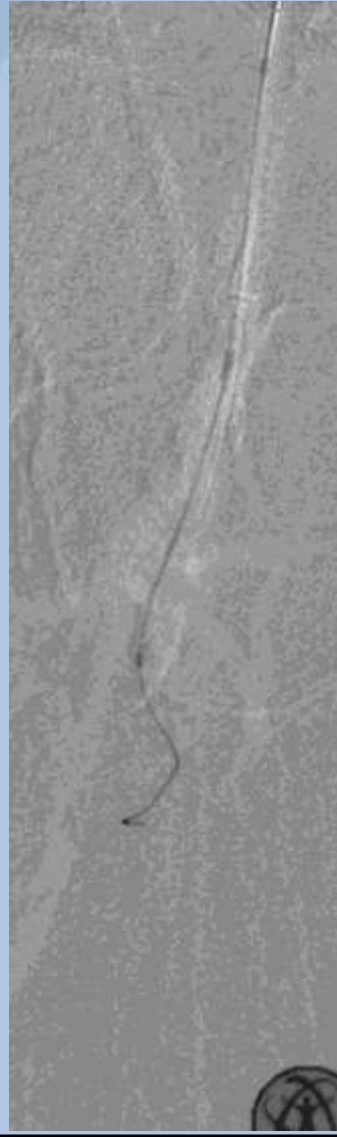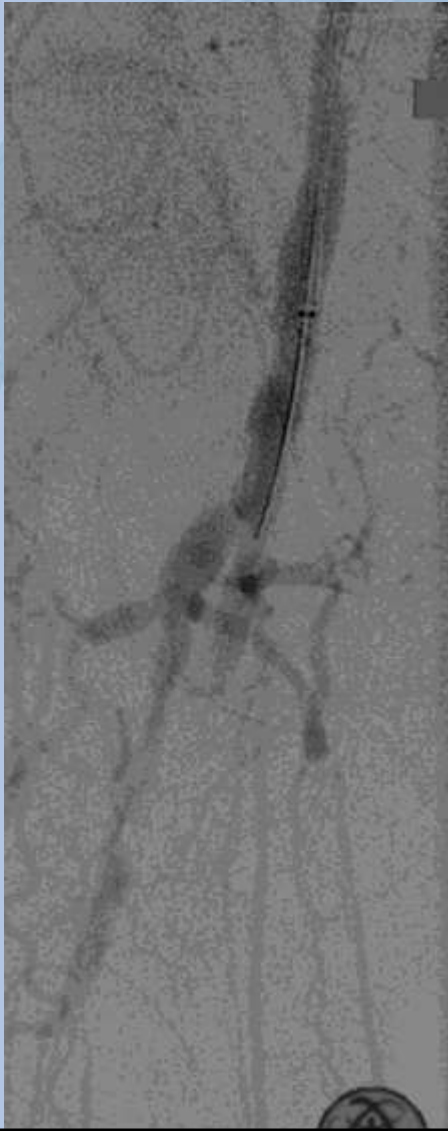


# Case

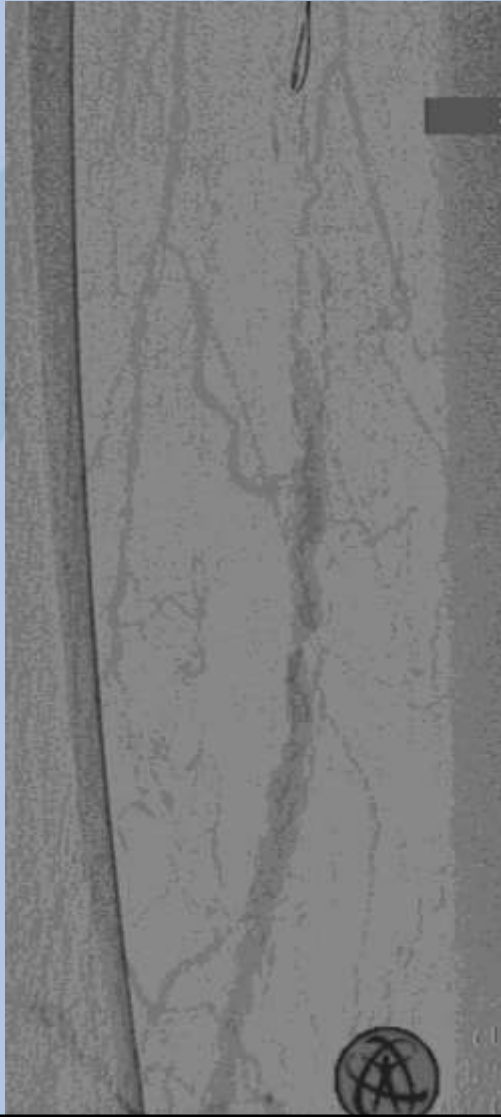
- **79 year old man**
- **Diabetes type 1**
- **Smoker >50 y**
- **Hypercholesterolaemia**
- **AHT**
- **PTCA/CABG**
- **Chronic renal insufficiency**
- **Rutherford Becker 5 : ulcers Toe 1,2,4 > 3months**
- **Rest pain**



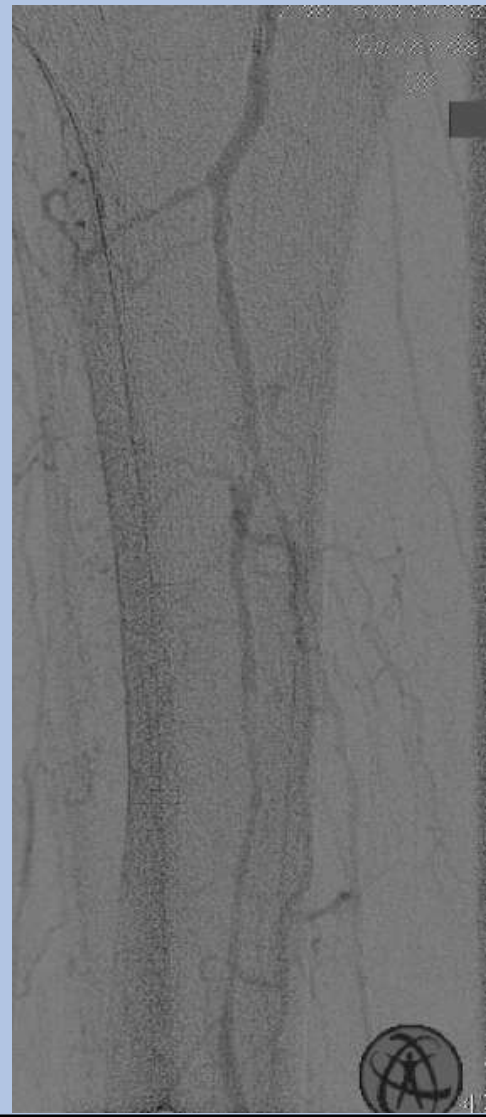

# Case



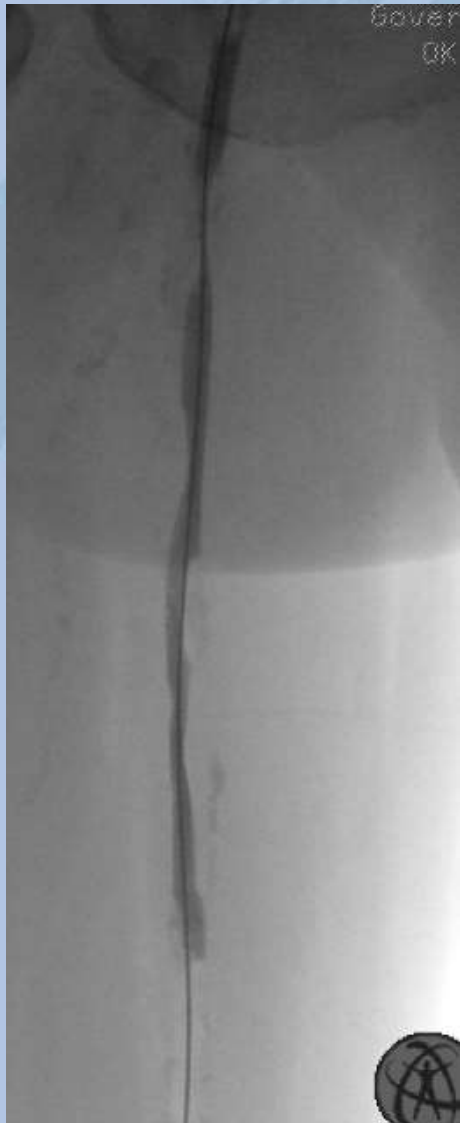
# Case



# Case

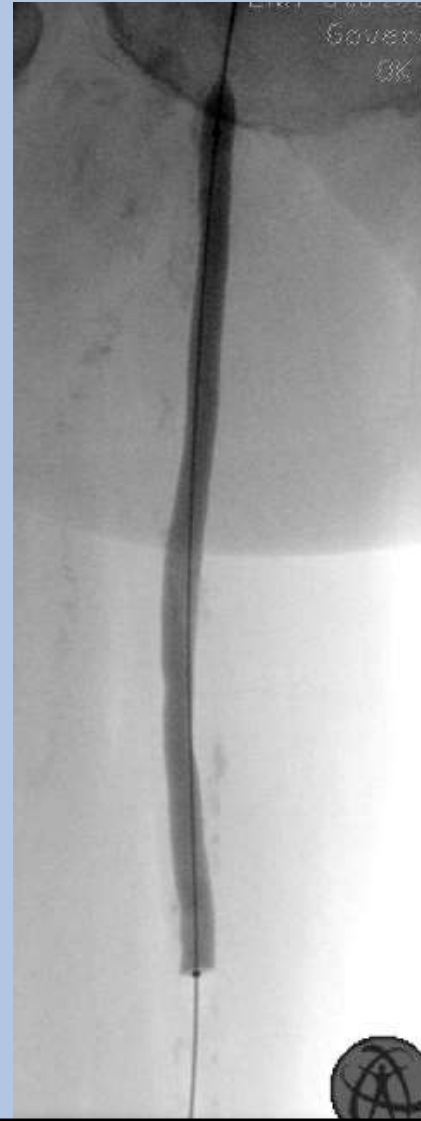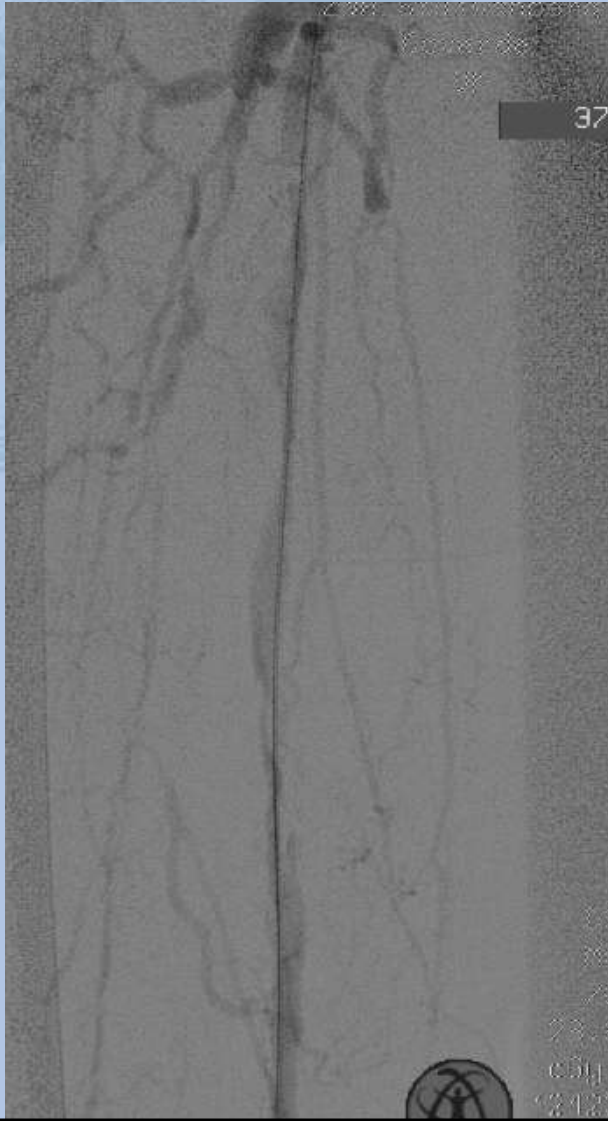


# Case

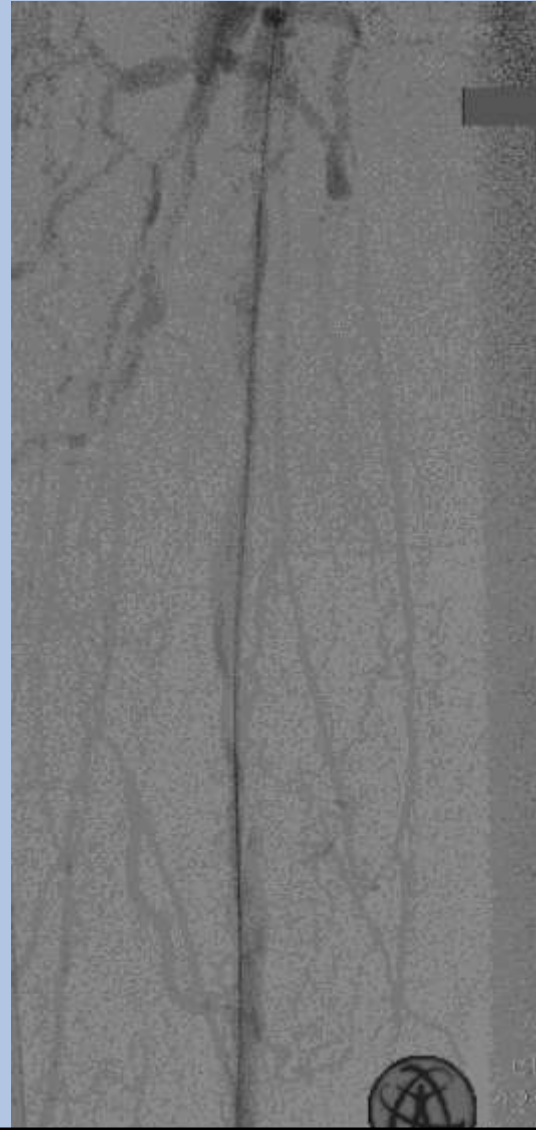




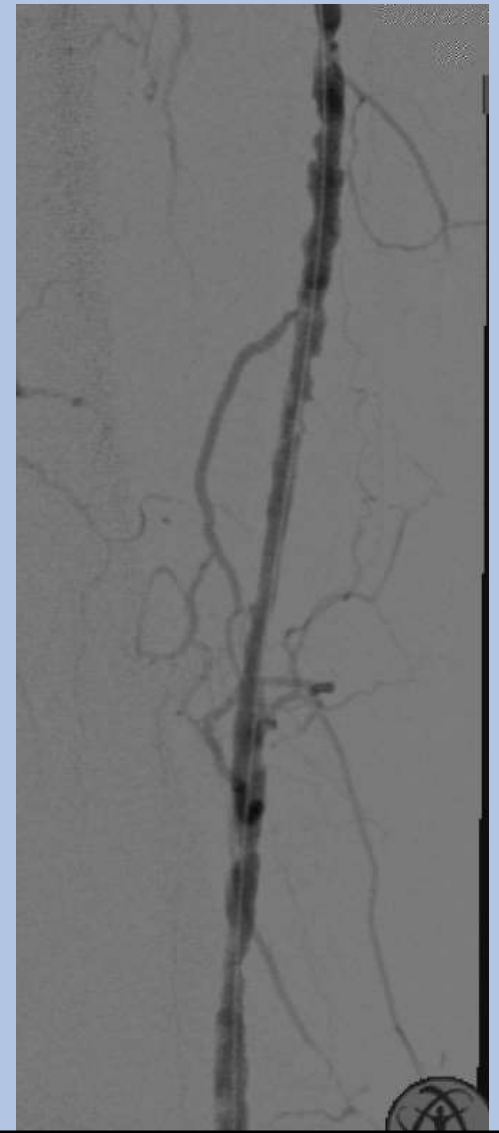
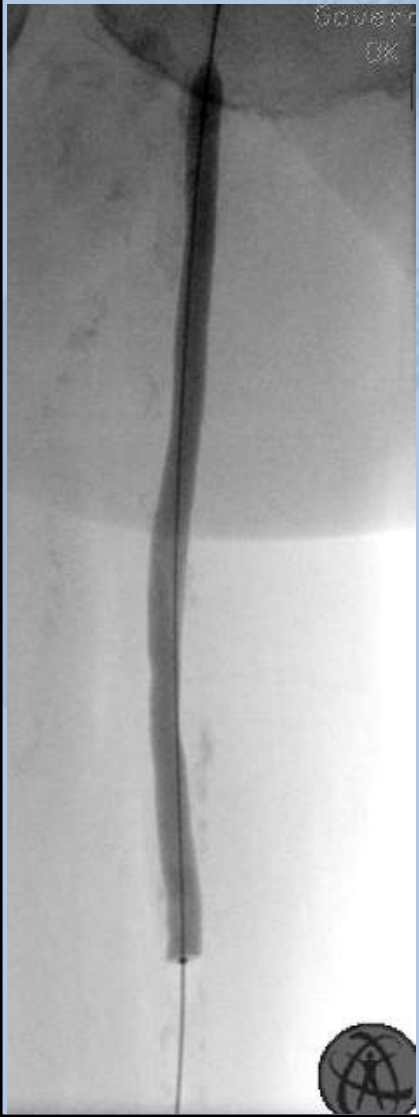
# Case



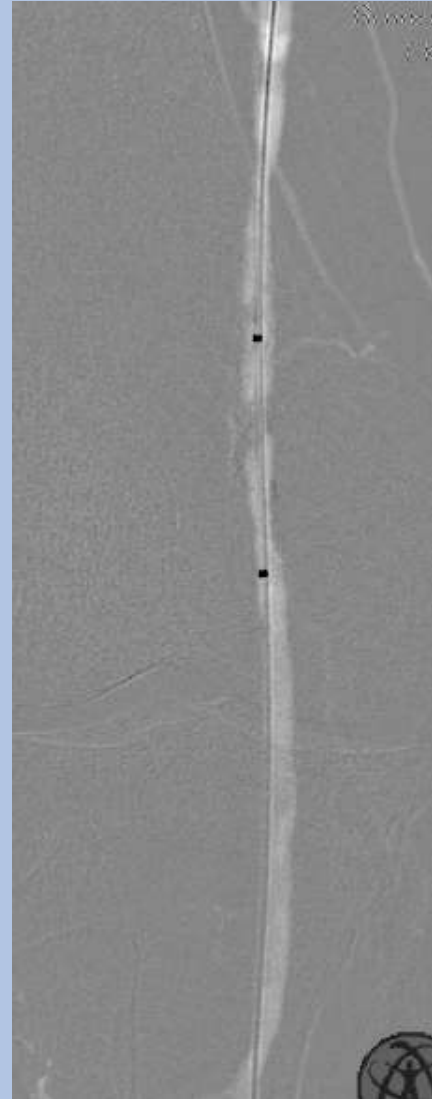
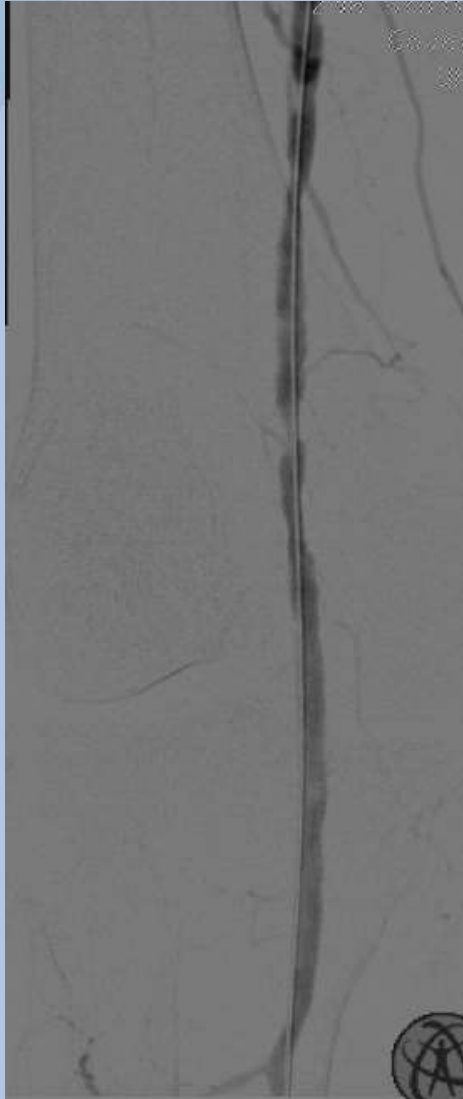# Case



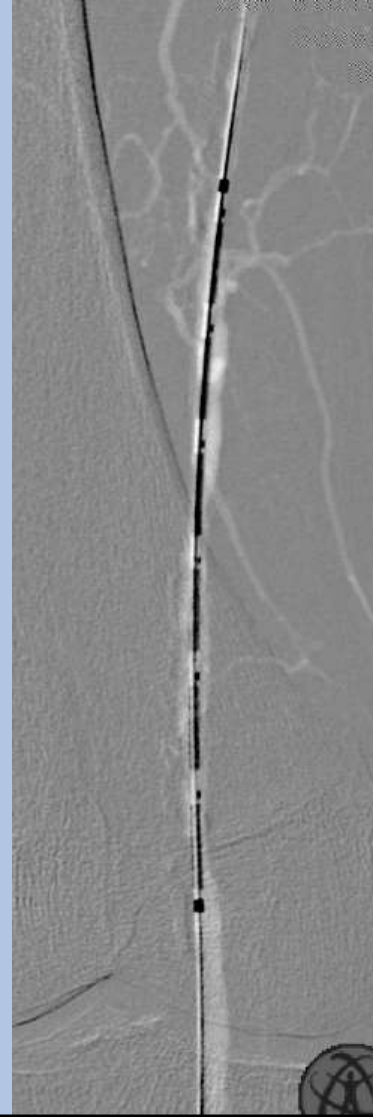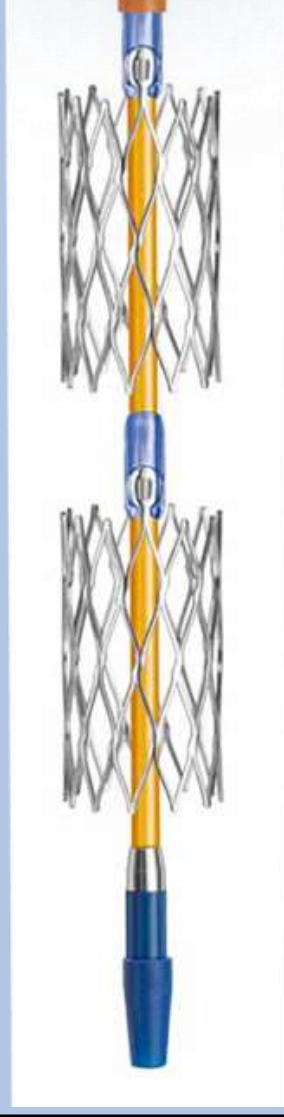
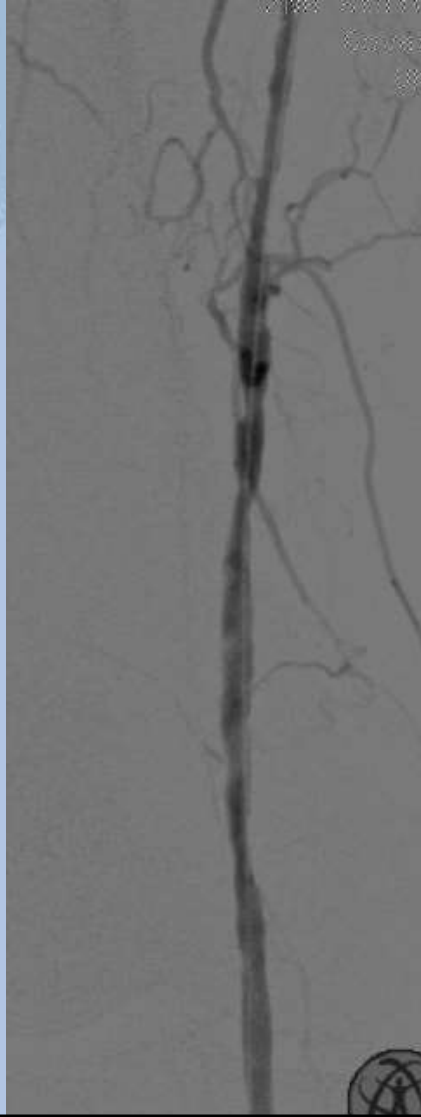
# Case

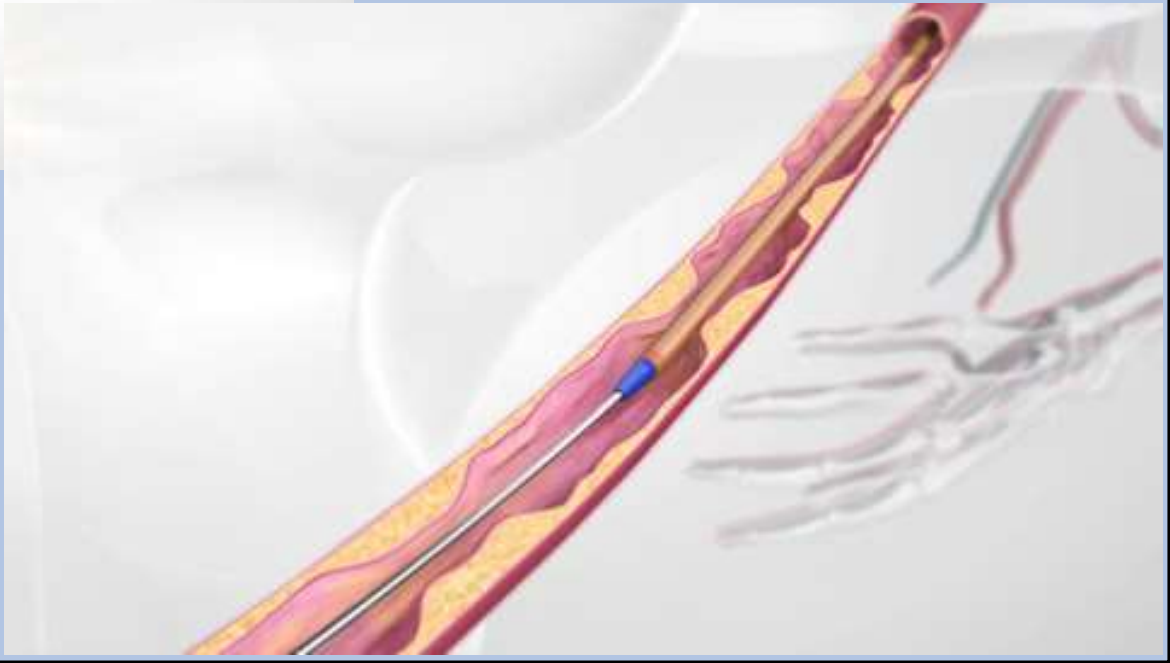



# Case



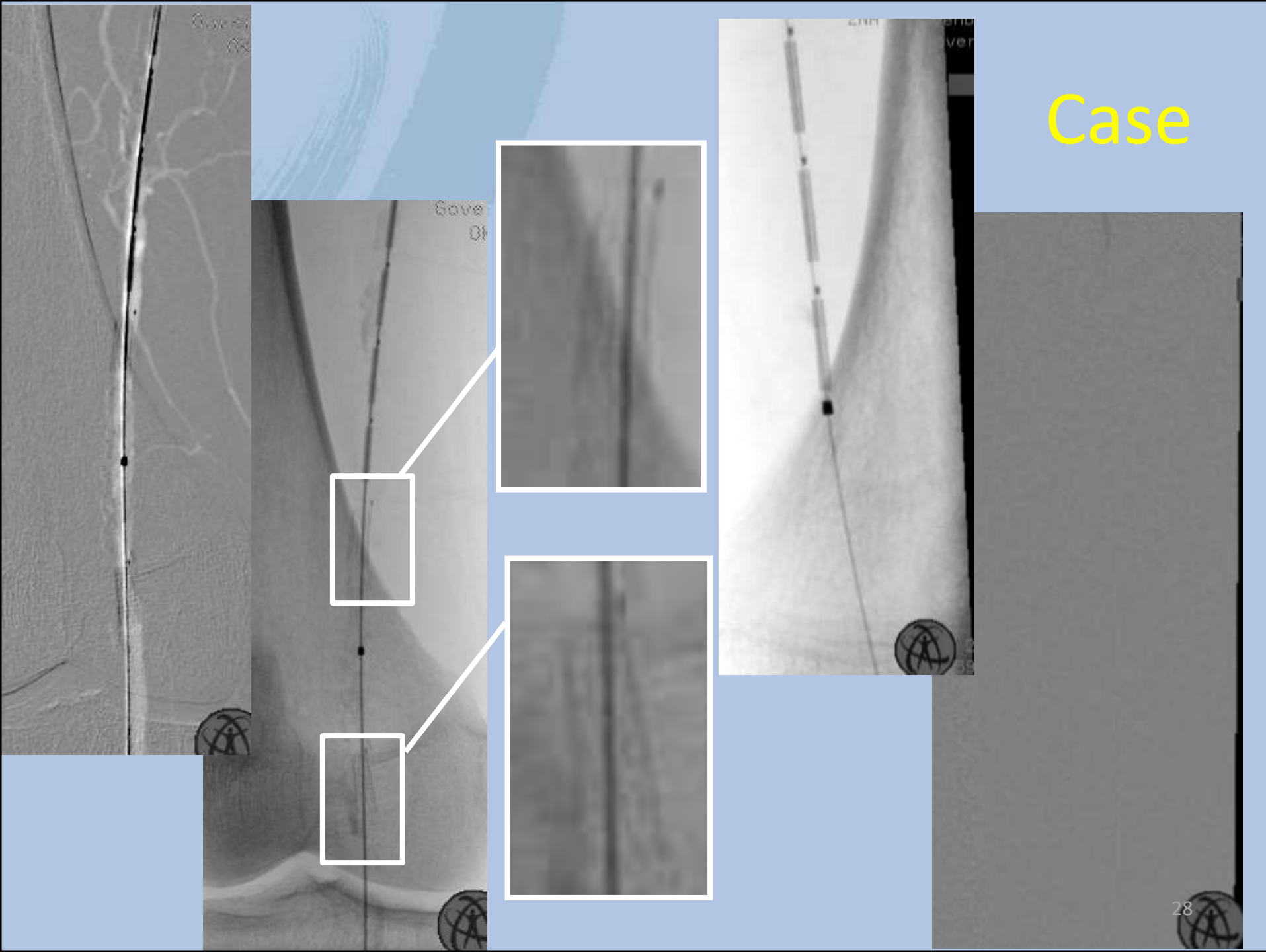
# Case



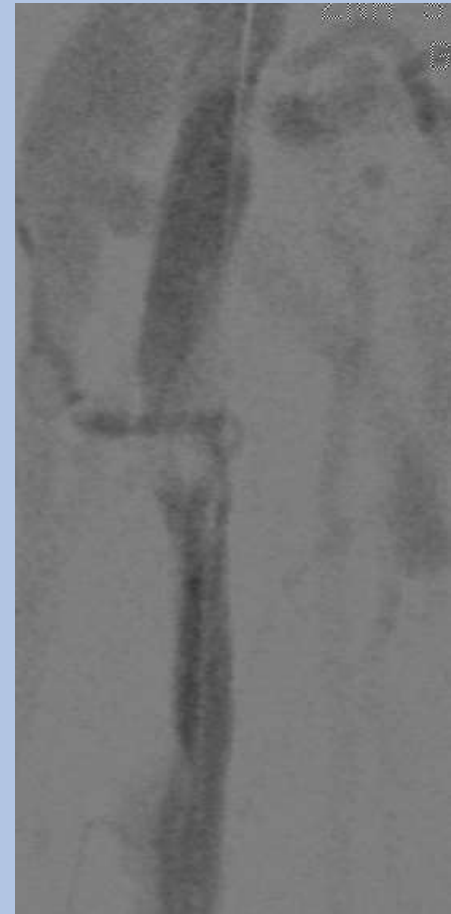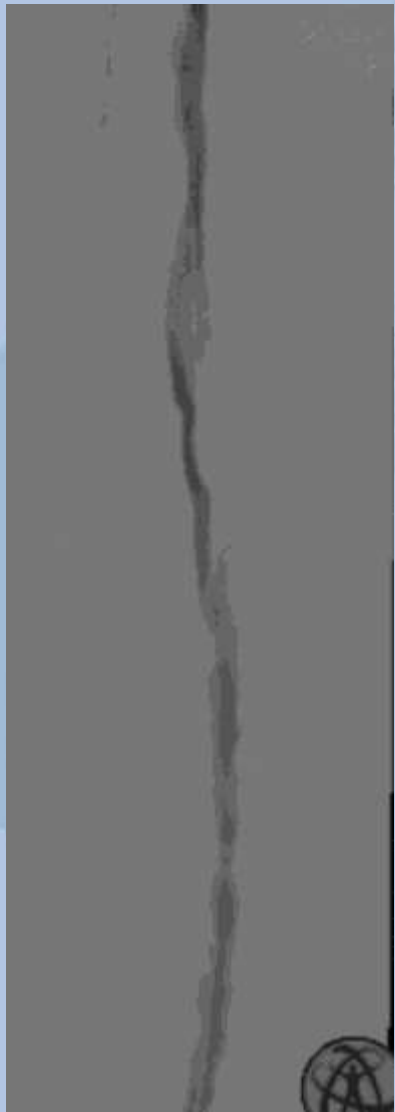




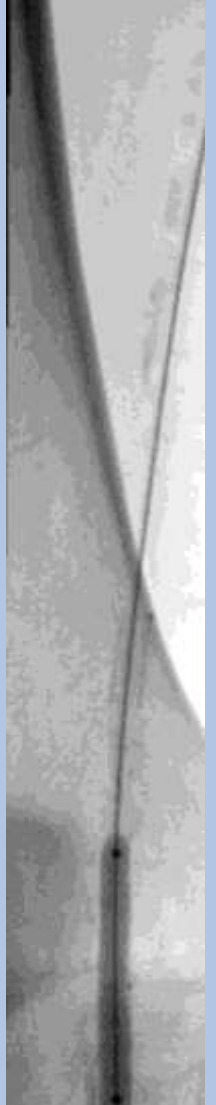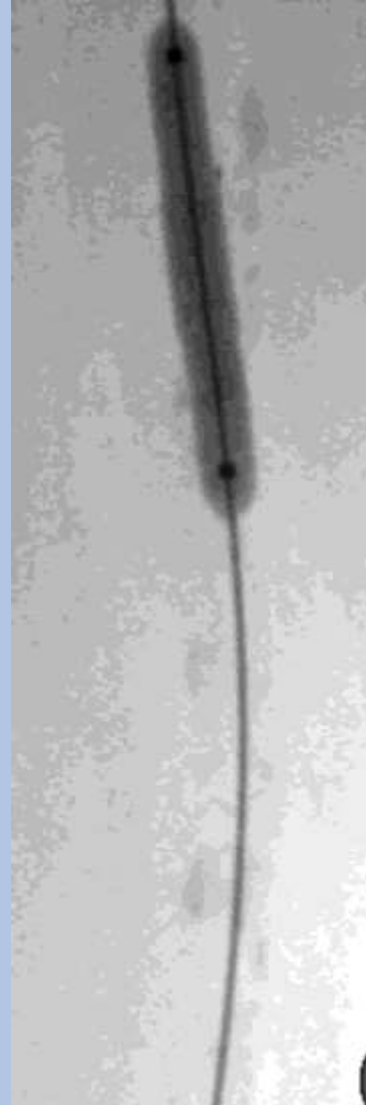

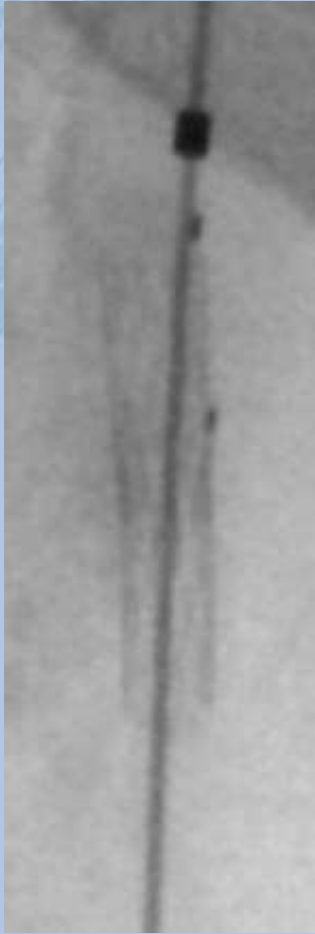
# Case





# Case



# Case



# Case

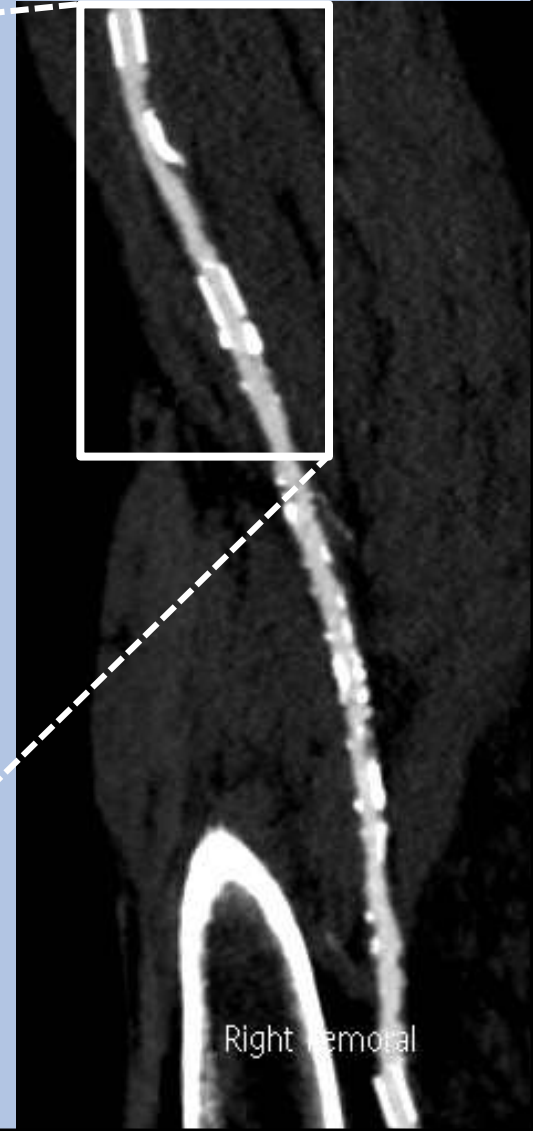
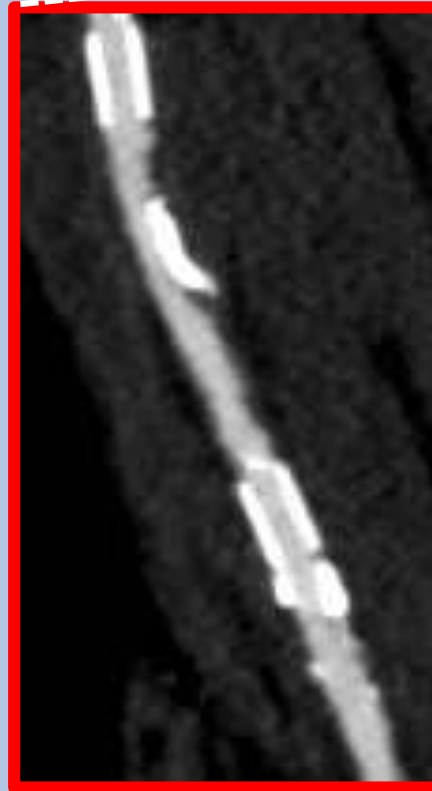
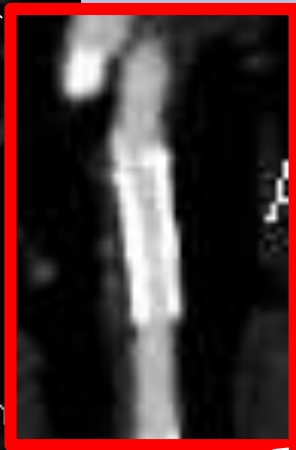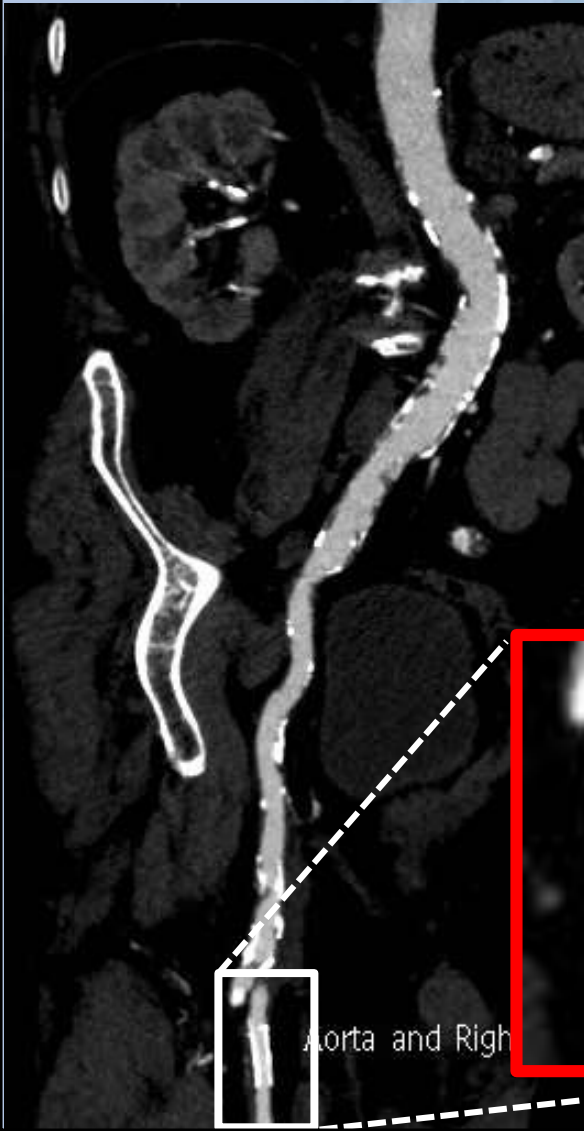Case

**Does it works ???**

# Case

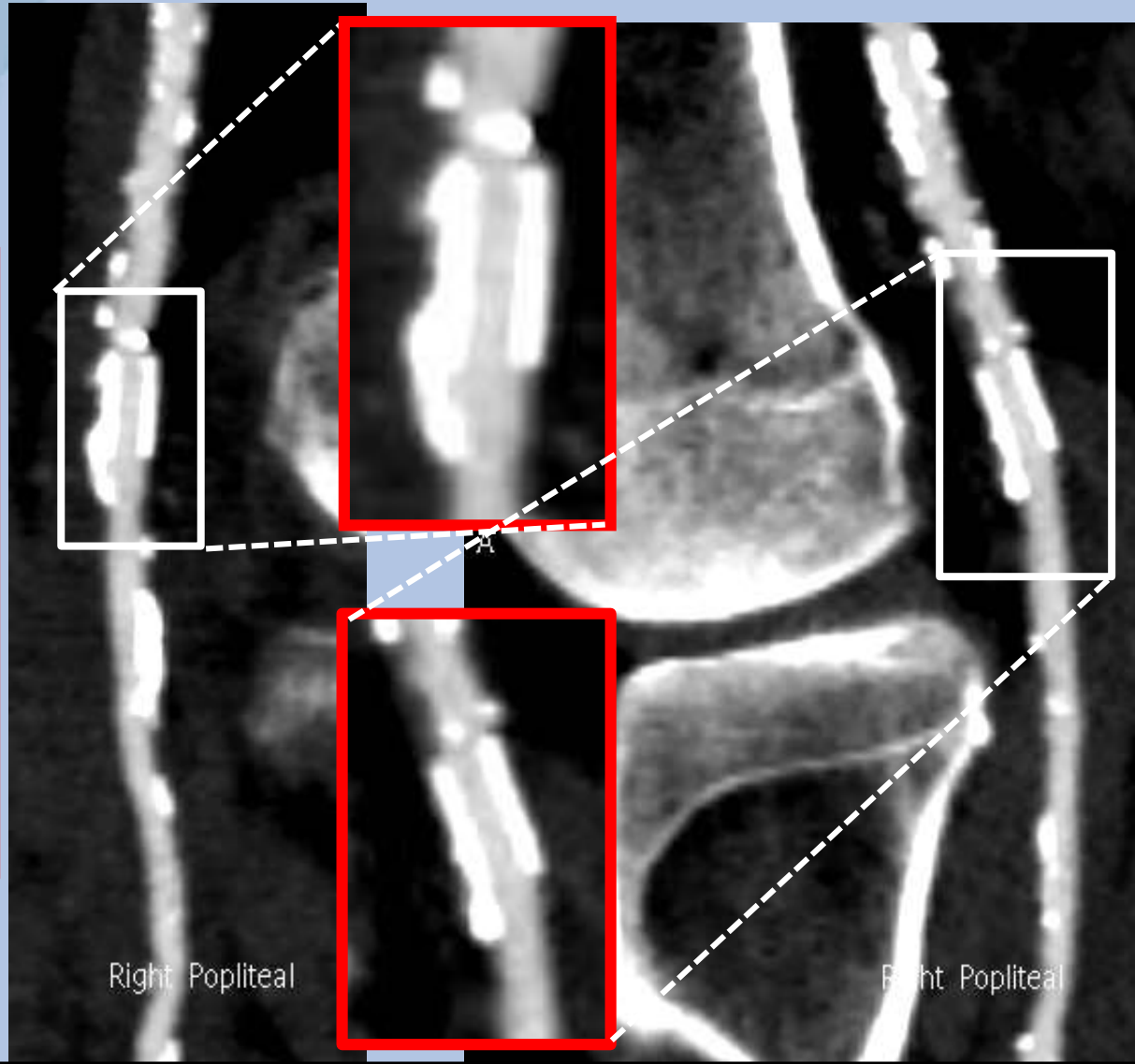
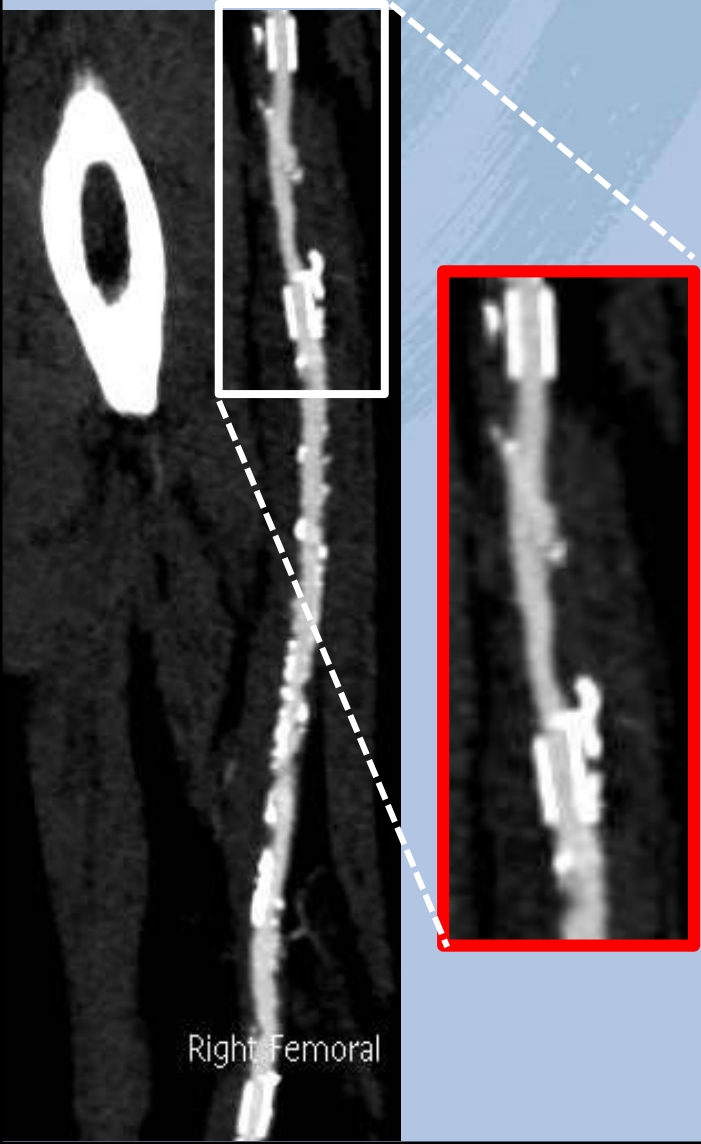
CT angio 3 months





# Case

CT angio 3 months

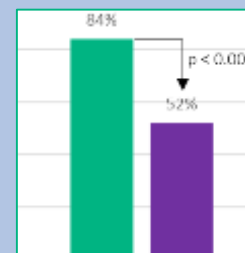
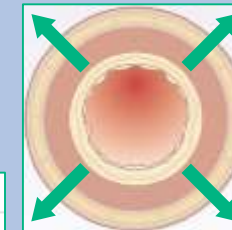
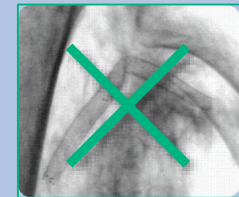




# Summary

## Rationale for spot stenting concept

- spot stenting overcomes the limitations of full metal jacket stenting by avoiding fracture, high TLR rates, and difficulties in fu ISR treatment. It also preserves surgical options.
- spot stenting maintains the natural motion of the fempop artery by leaving unstiffened artery segments to absorb the forces caused by limb movement. It reduces metal burden by 50%.
- spot stenting addresses fempop atherosclerosis challenges such as elastic recoil, calcium spots, and dissections
- spot stenting has demonstrated favourable clinical results in conceptual research (Hong et. al) and dedicated registries (LOCOMOTIVE)



# Conclusions

**We need still to go  
a long way**

**But we know that**

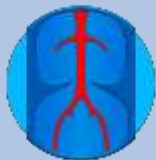**“less (stent) can be more”  
: the “Multi-Loc pathway”  
especially when combined  
with DCB**



The logo for LING, featuring a stylized blue and red shape resembling a flame or a brushstroke, with the word "LING" in white capital letters overlaid.

LING

# Spot Stenting with VascuFlex Multi-Loc



P. Goverde MD, K. Taeymans MD,  
K. Lauwers MD  
*Vascular Clinic ZNA  
Antwerp, Belgium*

